

Management of a Giant Posterior Uterine Leiomyoma: A Case Report

SONALI HARGUNANI¹, VARSHINI², POONAM NIKAM³

(CC) BY-NC-ND

ABSTRACT

Uterine leiomyomas, commonly referred to as fibroids, are the most frequent benign tumours of the uterus, primarily affecting women of reproductive age. Although these tumours are generally asymptomatic, their size and location can lead to significant clinical symptoms, including heavy menstrual bleeding, pelvic pain, and reproductive issues. The patient, a 31-year-old woman with a history of three pregnancies, presented with persistent abdominal pain, increased urinary frequency and dysmenorrhea over the past six months. Physical examination revealed an enlarged uterus corresponding to a 16-week pregnancy size, with a palpable mass suggestive of a uterine abnormality. Pelvic Ultrasound (USG) confirmed the presence of a large leiomyoma measuring 10×8.3×9 cm in the posterior uterine wall. Given the tumour's size and symptomatic presentation, surgical intervention was deemed necessary. The patient underwent a successful myomectomy, during which the leiomyoma was completely excised without complications. Postoperatively, the patient was closely monitored and discharged in stable condition. The surgical removal of the fibroid resulted in significant relief from her symptoms, improving her overall quality of life. This case underscores the importance of individualised surgical planning in the management of large uterine leiomyomas. The successful excision of the leiomyoma not only alleviated the patient's symptoms but also preserved her reproductive potential, highlighting the efficacy of surgical intervention in complex cases involving large fibroids.

Keywords: Fibroids, Minimally invasive surgery, Myomectomy, Reproductive health

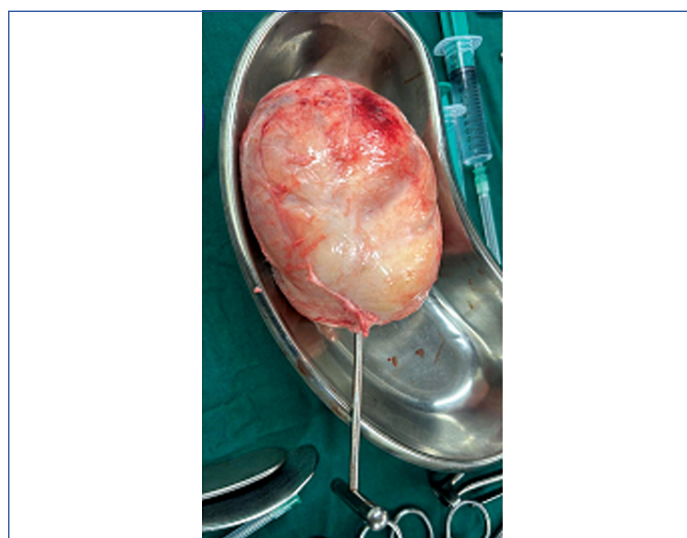
CASE REPORT

A 31-year-old gravida 3, para 1, abortion 1, living 1 (G3P1A1L1) presented with complaints of abdominal pain that had persisted for the past 5-6 months, along with increased frequency of urination and dysmenorrhea. The patient's obstetric history included a vaginal delivery of a male child three years prior and a spontaneous abortion six months earlier at two months of gestation. She had not undergone tubal ligation. On physical examination, the uterus was found to be enlarged to the size corresponding to a 16-week pregnancy and was non-tender on palpation. Per speculum examination revealed a healthy cervix and vagina. Per vaginal examination indicated a mass symmetrically covering the entire cervical wall with fullness in the posterior fornix, suggestive of a significant uterine abnormality.

A pelvic USG revealed a bulky uterus measuring 135×106×107 mm with a heterogeneous hypoechoic lesion measuring 100×83×90 mm located in the posterior uterine wall. The lesion exhibited minimal internal vascularity on colour doppler and caused a contoured bulge on the posterior uterine wall, indicative of an intrauterine fibroid. Both ovaries appeared normal with no additional masses or free fluid in the abdomen and pelvis.

Given the size and location of the fibroid, a decision was made to proceed with surgical intervention. The patient underwent a myomectomy, during which a leiomyoma (fibroid) measuring 10×8.3×9 cm was successfully excised from the posterior inferior aspect of the uterus [Table/Fig-1]. The surgery was uneventful, and the fibroid was completely removed without complications.

Postoperatively, the patient was monitored closely for any signs of complications. She recovered well and was discharged in stable condition after an appropriate period of observation. The removal of the fibroid was expected to alleviate her symptoms of abdominal pain, urinary frequency, and dysmenorrhea, significantly improving her quality of life. There were no complications seen postoperatively. The patient is having her regular menstrual cycle.



[Table/Fig-1]: Resected uterine fibroid.

DISCUSSION

Uterine leiomyomas, commonly known as fibroids, are the most prevalent benign tumours of the uterus, primarily affecting women of reproductive age. These tumours originate from smooth muscle cells and, while most frequently associated with the uterus, can also develop in other locations such as the oesophagus, stomach, and prostate. Despite being benign, leiomyomas can pose significant clinical challenges depending on their size, location, and the severity of symptoms they cause [1].

The clinical manifestations of giant leiomyomas often include progressive abdominal distension, pelvic pain, pressure symptoms on adjacent organs, and abnormal uterine bleeding [1,2]. However, the absence of definitive preoperative imaging to rule out malignancy is a frequent concern, as seen in cases where large fibroids mimic

ovarian or malignant tumours [3,4]. The present case aligns with these findings, emphasising the need for thorough preoperative assessment and differential diagnosis.

A critical consideration in managing giant fibroids is the risk of complications such as hydronephrosis, bowel obstruction, and deep vein thrombosis due to mass effect [5,6]. Some reports describe cases where fibroids led to significant urinary symptoms, necessitating additional interventions [7,8]. Similarly, the present case experienced compression symptoms requiring careful intraoperative planning.

Fertility preservation remains a major concern in younger patients with large leiomyomas. A case of a 17-year-old adolescent successfully managed with fertility-sparing myomectomy demonstrates that preserving reproductive potential is possible even in the presence of large fibroids [9]. In contrast, for postmenopausal women or those with significant comorbidities, hysterectomy is often the preferred approach [10,11]. This case underscores the importance of individualised surgical decision-making based on patient age, symptoms, and reproductive goals.

Surgical challenges in giant leiomyomas include increased vascularity, distorted anatomy, and the risk of intraoperative haemorrhage. Several reports highlight the use of preoperative Gonadotropin-Releasing Hormone (GnRH) analogs to shrink fibroid size and reduce blood loss [12,13]. However, in cases where surgery is inevitable due to symptom severity, careful intraoperative haemostasis, as achieved in our case, is essential [14,15]. Other intraoperative strategies such as uterine artery embolisation and minimally invasive approaches have also been explored in the literature to mitigate surgical risks and improve outcomes [4,16].

Rare variants of leiomyomas, such as lipoleiomyomas and leiomyomas associated with genetic mutations (e.g., fumarate hydratase deficiency), have been reported in the literature [15,16]. While these variants may have different clinical implications, their presence underscores the need for histopathological evaluation of all excised specimens. Additionally, the role of molecular and genetic testing in identifying potential malignancy or recurrence risk is an evolving area of research that warrants further investigation.

Postoperative recovery and long-term follow-up are crucial in preventing recurrence and ensuring optimal patient outcomes. Most studies report favourable long-term outcomes with either myomectomy or hysterectomy, depending on the surgical approach taken [4,11]. However, postsurgical complications such as adhesion formation, residual fibroid growth, and reproductive challenges must be considered. Close surveillance with periodic imaging and patient counselling on potential late complications should be integral to follow-up care.

The complexity of managing giant uterine leiomyomas requires a multidisciplinary approach, integrating expertise from gynaecologic surgeons, radiologists, pathologists, and reproductive specialists. A tailored approach that balances symptom relief, fertility considerations,

and long-term patient well-being remains the cornerstone of effective management.

CONCLUSION(S)

The successful surgical management of a large posterior uterine leiomyoma, as presented in this case, highlighted the complexities involved in treating such significant gynaecological tumours. The size and location of the leiomyoma posed considerable challenges, particularly in terms of surgical accessibility and the potential for intraoperative complications. However, through meticulous preoperative planning, effective intraoperative management, and a focus on preserving fertility, the surgery was successfully completed with a favourable outcome.

REFERENCES

- Lim PT, Tan CH, Chia HL, Phoon J. Management of a giant uterine leiomyoma. *BMJ Case Rep.* 2018;2018:bcr2017224052. Doi: 10.1136/bcr-2017-224052.
- Panayotidis C, Salleh S, Martin JE, Hirsh P, Wynn J. Giant uterine leiomyomas: Dilemmas in surgical management. *Gynecological Surgery.* 2006;3:37-40. Available from: <https://doi.org/10.1007/s10397-005-0149-x>.
- Sowjanya SB, Patil V, Gusain N, Sawant T. Surgical challenges in unusual fibroids - a case series. *Int J Reprod Contracept Obstet Gynecol.* 2022;11(10):2826-32. Available from: <https://doi.org/10.18203/2320-1770.ijrcog2022483>.
- Singh V, Shinde S, Shinde N. Dilemma in diagnosis of giant uterine fibroid: Case Report. *International Journal.* 2021;4(2):633.
- Vilos GA, Allaire C, Loberge PY, Leyland N. Special contributors. The management of uterine leiomyomas. *J Obstet Gynaecol Can.* 2015;37(2):157-78. Doi: 10.1016/S1701-2163(15)30338-8.
- Yamamoto A, Suzuki S. Successful surgical treatment of a giant uterine leiomyoma: A case report. *Int J Surg Case Rep.* 2021;87:106416. Doi: 10.1016/j.ijscr.2021.106416.
- Vellanki VS, Rao M, Sunkavalli CB, Chinamotu RN, Kaja S. A rare case of uterine leiomyosarcoma: A case report. *J Med Case Rep.* 2010;4:222. Doi: 10.1186/1752-1947-4-222.
- Brito LG, Ueno NL, Machado MR. Does big mean evil? Giant, but benign uterine leiomyoma: Case report and review of the literature. *Revista Brasileira de Ginecologia e Obstetrícia/RBGO Gynecology and Obstetrics.* 2021;43(01):066-71.
- Barahmeh S, Shrateh ON, Jobran AWM, Hamarsheh L, Tanib I, Alwahsh MJ. Rare clinical entity of huge leiomyoma uteri in a 17-year-old adolescent managed with a fertility-sparing procedure: Case report and literature review. *Int J Surg Case Rep.* 2023;107:108367. Doi: 10.1016/j.ijscr.2023.108367.
- Alsaif JM, Alali ZS, Elsharkawy T, Ahmed A. Uterine lipoleiomyoma: A case report and review of literature. *Cureus.* 2021;13(12):e20297. Doi: 10.7759/cureus.20297.
- Wilke S, Benson J, Roller L. Uterine lipoleiomyoma: Case report and review of the literature. *Radiol Case Rep.* 2022;17(3):954-58.
- Almusaylim MS, Darwish FA, Alahmad FA, Alsaleh MA, Almohammedsaleh MM. Large submucosal uterine leiomyoma prolapse into the vagina after complicating a pregnancy: A case report. *Cureus.* 2023;15(11):e49116. Doi: 10.7759/cureus.49116.
- Ahmed S, Ahmed S, Gullabzada M, Gullabzada U, Jobanputra K. Abnormal uterine bleeding with leiomyomas: A case report of its natural course and therapeutic management. *Cureus.* 2024;16(9):e69153. Doi: 10.7759/cureus.69153.
- Defran AJ, Forestier C, Morgan E, Thomas M. Uterine leiomyoma in the context of uterine didelphys: A case report. *Cureus.* 2023;15(9):e44791. Doi: 10.7759/cureus.44791.
- Huang Y, Zhou Y, Chen X, Fang Q, Cai H, Xie M, et al. Uterine leiomyoma with fumarate hydratase deficiency: A case report. *Medicine (Baltimore).* 2021;100(49):e28142. Doi: 10.1097/MD.00000000000028142.
- Exarchos G, Vlahos N, Dellaportas D, Metaxa L, Theodosopoulos T. Incarcerated giant uterine leiomyoma within an incisional hernia: A case report. *Clin Case Rep.* 2017;5(11):1837-40.

PARTICULARS OF CONTRIBUTORS:

- Senior Resident, Department of Obstetrics and Gynaecology, Dr. D. Y. Patil Medical College, Hospital and Research Centre, Pune, Maharashtra, India.
- Resident, Department of Obstetrics and Gynaecology, Dr. D. Y. Patil Medical College, Hospital and Research Centre, Pune, Maharashtra, India.
- Research Co-ordinator, Department of Central Research Facility, Dr. D. Y. Patil Medical College, Hospital and Research Centre, Pune, Maharashtra, India.

NAME, ADDRESS, E-MAIL ID OF THE CORRESPONDING AUTHOR:

Varshini,
Dr. D. Y. Patil Medical College, Hospital and Research Centre, Sant Tukaram Nagar,
Pimpri, Pune-411018, Maharashtra, India.
E-mail: drvarshini.27@gmail.com

AUTHOR DECLARATION:

- Financial or Other Competing Interests: None
- Was informed consent obtained from the subjects involved in the study? Yes
- For any images presented appropriate consent has been obtained from the subjects. Yes

PLAGIARISM CHECKING METHODS: [Jain H et al.]

- Plagiarism X-checker: Nov 20, 2024
- Manual Googling: Feb 11, 2025
- iThenticate Software: Feb 13, 2025 (6%)

ETYMOLOGY: Author Origin

EMENDATIONS: 6

Date of Submission: Nov 19, 2024

Date of Peer Review: Jan 06, 2025

Date of Acceptance: Feb 15, 2025

Date of Publishing: Jun 01, 2025